

# Current state of bone scintigraphy protocols and practice in Japan

Hajime Ichikawa<sup>1</sup>, Kenta Miwa<sup>2</sup>, Koichi Okuda<sup>3</sup>, Takayuki Shibutani<sup>4</sup>, Toyohiro Kato<sup>1</sup>, Akio Nagaki<sup>5</sup>, Hiroyuki Tsushima<sup>6</sup>, Masahisa Onoguchi<sup>4\*</sup>

<sup>1</sup> Department of Radiology, Toyohashi Municipal Hospital, Toyohashi, Japan

<sup>2</sup> Department of Radiological Sciences, School of Health Sciences, International University of Health and Welfare, Tochigi, Japan

<sup>3</sup> Department of Physics, Kanazawa Medical University, Kanazawa, Japan

<sup>4</sup> Department of Quantum Medical Technology, Institute of Medical, Pharmaceutical and Health Sciences, Kanazawa University, Kanazawa, Japan

<sup>5</sup> Department of Radiological Technology, Kurashiki Central Hospital, Kurashiki, Japan

<sup>6</sup> Department of Radiological Sciences, Ibaraki prefectural University of Health Sciences, Ibaraki, Japan

## ARTICLE INFO

### Article type:

Short Communications

### Article history:

Received: 9 Dec 2019

Revised: 13 Feb 2020

Accepted: 18 Feb 2020

### Keywords:

Bone scintigraphy

Nationwide survey

Routine scan protocol

Additional imaging

Omission of scan

protocol

## ABSTRACT

**Objective(s):** Nuclear medicine technologists in Japan often perform additional single-photon emission computed tomography (SPECT) with or without computed tomography (CT) after whole-body imaging for bone scintigraphy. In this study, we wanted to identify the bone scanning protocols used in Japan, together with the current clinical practices.

**Methods:** The study was conducted between October and December 2017. We created a web survey that was hosted by the Japanese Society of Radiological Technology. The questionnaire included 12 items regarding the demographics of the responders, their scan protocols, and the imaging added to, or omitted from, routine protocols.

**Results:** In total, 228 eligible responses were collected from participants with a mean of  $11.6 \pm 8.4$  years' experience in nuclear medicine examination. All responders reported using routine scan protocols that included whole-body imaging. However, only 2%, 4%, 20%, and 14% of the responders also acquired single-field SPECT, single-field SPECT/CT, multi-field SPECT, and multi-field SPECT/CT, respectively.

**Conclusion:** Our survey results indicate that nuclear medicine practice in Japan is beginning to shift from planar whole-body imaging with additional spot planar images to additional SPECT or SPECT/CT. Further study is required to examine the optimal protocols for bone scintigraphy.

►Please cite this paper as:

Ichikawa H, Miwa K, Okuda K, Shibutani T, Kato T, Nagaki A, Tsushima H, Onoguchi M. Current state of bone scintigraphy protocols and practice in Japan. Asia Ocean J Nucl Med Biol. 2020; 8(2):116-122. doi:10.22038/AOJNMB.2020.44923.1302

## Introduction

Bone scintigraphy has been used to detect bone metastases in patients with cancer for several decades, and remains the most frequently performed nuclear medicine examination in Japan (1). Scans typically rely on a whole-body sweep technique, although additional planar scans (e.g., lateral or oblique views) or single-photon emission computed tomography (SPECT) scans

may also be performed where there is bone-on-bone overlap or to improve the determination of whether malignant lesions are present. Whole-body planar images retain a pivotal role in determining the presence or absence of bone metastases, but it is not easy to interpret planar bone scintigraphy. Indeed, because diagnostic accuracy varies largely by physician experience (2), Sadik et al. (3) developed a computer-assisted

\* Corresponding author: Masahisa Onoguchi. 5-11-80 Kodatsuno, Kanazawa, Ishikawa, 9200942, Japan. Tel: +81-76-265-2526; Fax: +81-76-265-2526; E-mail: onoguchi@staff.kanazawa-u.ac.jp

© 2020 mums.ac.ir All rights reserved.

This is an Open Access article distributed under the terms of the Creative Commons Attribution License (<http://creativecommons.org/licenses/by/3.0>), which permits unrestricted use, distribution, and reproduction in any medium, provided the original work is properly cited.

system to improve the sensitivity of whole-body imaging for detecting bone metastases and to reduce inter-observer variation. However, its lower contrast can impair lesion detection, and many technologists are still unfamiliar with the commercially available noise reduction equipment that can improve detection on planar images (4).

Several studies have recently investigated the diagnostic accuracy of multi-field SPECT (5-7) and SPECT with computed tomography (CT) (8-11). Utsunomiya et al. reported that planar and SPECT images are often insufficient to precisely localize bone lesions (11), whereas some studies have reported that the diagnostic accuracy for detecting malignant lesions exceeds 90% when SPECT is included (12-15). Existing data indicate that higher diagnostic accuracy can be achieved with SPECT/CT than with SPECT alone, just as SPECT is superior to planar imaging. Although this suggests that whole-body SPECT/CT scanning can replace whole-body planar scans, but not so in fact. Shafi et al (16). have developed criteria to determine when SPECT/CT scan should be added to a whole-body planar scan; however, differences between institutes in Japan indicate that no unified criteria exist for using additional SPECT imaging in bone scintigraphy.

The availability of SPECT/CT systems in Japan doubled from 153 to 314 in the past five years (1). However, the current state of SPECT or SPECT/CT scanning in patients undergoing bone

scintigraphy is still unclear, and the absence of a unified scan protocol could lead to variations in diagnostic accuracy among sites. Moreover, in Japan, nuclear medicine technologists occasionally decide the addition or omission of a scan in a routine scan protocol. We must therefore clarify actual bone scintigraphy examination. The aim of the present study looks to document current protocols of bone scintigraphy in Japan.

## Methods

This study was approved by the Human Research Ethics Committee of Toyohashi Municipal Hospital and conducted between October 2nd and December 20th, 2017. We created a web survey that was hosted by the Japanese Society of Radiological Technology, and we mailed the link to approximately 9,000 of their members who were subscribed to an e-mail newsletter. (However, the members of belonging to the subgroup of nuclear medicine section are approximately 450.) The questionnaire included 12 items regarding the demographics of the responders, their scan protocols, and the imaging they added to, or omitted from, routine protocols (Table 1). Consent was assumed when a response was received. We provided an explanation on the website that consent could not be withdrawn after completing the questionnaires because of the anonymous nature of the data collection.

**Table 1.** The 12-item questionnaire survey distributed to nuclear medicine technologists

Demographics	
Q1	Type of medical institution: university hospital, public hospital, private hospital, other
Q2	How many years of experience in nuclear medicine examination do you have?
Q3	Are you a board-certified nuclear medicine technologist?
Q4	What kind of equipment do you use?: SPECT imaging systems, SPECT/CT imaging systems, planar imaging systems, others
Routine protocol	
Q5	Do you have a routine scan protocol for bone scintigraphy at your site?: y/n
Q6	In your routine protocol, which body parts do you scan and how do you scan them?: whole body, head and neck, thorax, lumbar, pelvis, femoral, cervical spine to pelvis, other, planar imaging (anterior/lateral/oblique view), SPECT, SPECT/CT
Q7	Do you use image processing for whole-body images?: CAD system, noise reduction, other
Q8	What type of SPECT image do you reconstruct?: FBP; OSEM without RR; OSEM with RR, without SC and AC, with AC, with SC, with SC and AC; quantitative analyses using SUV and SPECT/CT fusion imaging; additional image fusion software; other
Added and omitted imaging	
Q9	Will you add or omit to routine scan protocol?: y/n
Q10	How do you determine addition or omission to routine scan protocol?: institute guideline, consultation with physician, decision by technologist, other
Q11	Which body parts do you scan and how do you scan them in added and/or omitted imaging?: whole body; head and neck; thorax; lumbar; pelvis; femoral; cervical spine to pelvis; planar imaging, such as anterior, lateral, oblique view; SPECT; SPECT/CT; CT; other
Q12	What are the criteria and evidence considered?: initial examination, follow-up examination, same as the previous examination, change in the previous examination, presence of abnormal lesions, absence of abnormal lesions, site of pain, agreement for each disease, previous studies, experimental rules, no evidence, other

Abbreviations: AC, attenuation correction; CAD, computer-assisted diagnosis; CT, computed tomography; FBP, filtered back-projection; OSEM, ordered subset expectation maximization; RR, resolution recovery; SC, scatter correction; SPECT, single-photon emission computed tomography; SUV, standardized uptake value

## Results

### Respondents

A total of 228 eligible responses were collected. The highest number of responses was collected from public hospitals (37%), followed by private hospitals (31%), university hospitals (29%), and other (2%). The mean experience as a nuclear medicine technologist of all the responders was  $11.6 \pm 8.4$  years, but many (43%) had >10 years' experience. Almost half of the responders (47%) were board-certified nuclear medicine technologists. SPECT and SPECT/CT systems were available to 53% and 47% of the responders, respectively. No responders used planar imaging or other systems. Consequently, SPECT/CT systems were available at 73% of university hospitals, 42% of public hospitals, and 31% of private hospitals.

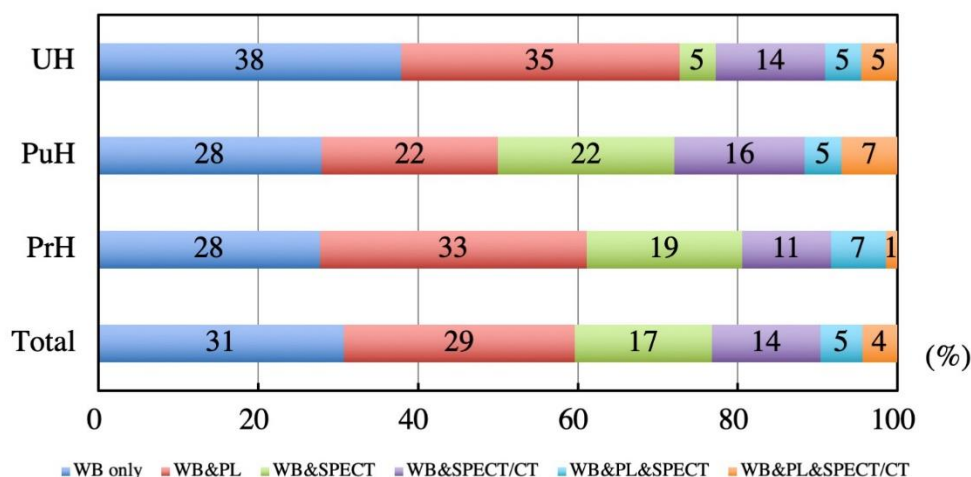
### Routine protocol

All responders indicated that they had a routine scan protocol for bone scintigraphy, typically including whole-body imaging. Beyond whole-body imaging, the highest number of responses in body region was thorax (61%), lumbar (41%), head and neck (25%), and cervical vertebra to pelvis (14%) (Table 2). Almost 60% of the responders did not acquire SPECT routinely (Figure 1), though the frequency of SPECT or SPECT/CT acquisition was highest in public hospitals (50%). Single-field SPECT and SPECT/CT were acquired by 2% and 4% of the responders, respectively; the corresponding rates for multi-field SPECT and SPECT/CT acquisition were 20% and 14%, respectively.

**Table 2.** Body parts scanned and percentage of cases with respect to methods used in routine protocols

	Anterior view	Lateral view	Oblique view	SPECT	SPECT/CT	% Total
Head and neck	5	9	1	7	4	25
Thorax	16	2	21	14	7	61
Lumbar	15	2	4	15	6	41
Pelvis	7	0	1	0	3	11
Femoral	0	0	0	1	1	2
Spine and pelvis	1	0	0	6	7	14
Others	2	1	0	2	2	7

Abbreviations: CT, computed tomography; SPECT, single-photon emission computed tomography



**Figure 1.** Responses to the question "How do you scan in your routine protocol"?

Routine scan protocols are as follows: WB only; WB&PL; WB&SPECT; WB&SPECT/CT; WB&PL&SPECT; and WB&PL&SPECT/CT. Responses were received from 66 UH, 86 PuH, and 72 PrH.

Abbreviations: CT, computed tomography; PL, planar imaging; PrH, private hospital; PuH, public hospital; SPECT, single-photon emission computed tomography; UH, university hospital; WB, whole-body

Approximately half of the responders (52%) used a computer-assisted diagnosis system, such as the BONENAVI system (FUJIFILM Toyama Chemical Co., Ltd.) (17). A minority (16%) used noise reduction processing for whole-body imaging, while most (63%) used ordered subsets expectation maximization with resolution

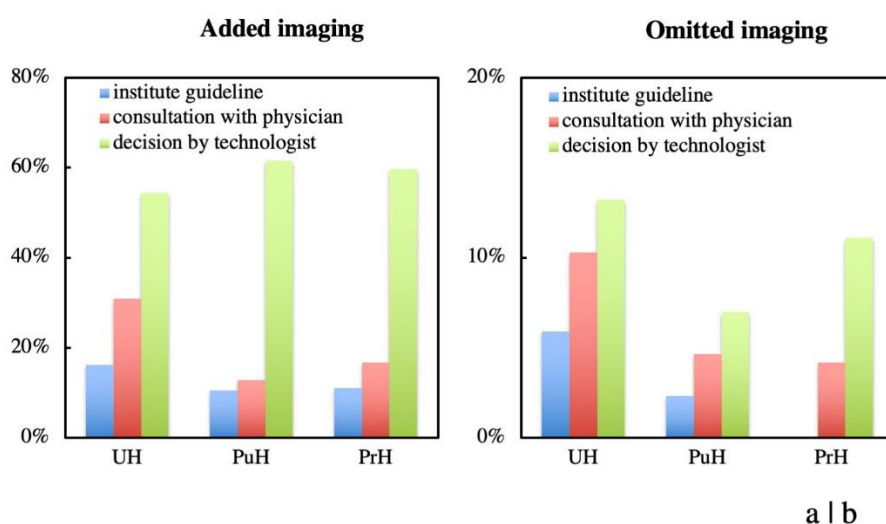
recovery. The responses to the question for each correction in SPECT image were comparable with (41%) and without (42%) both scatter and attenuation correction. Quantitative SPECT images were reconstructed by 24 out of the 92 SPECT or SPECT/CT performing responders (26%), SPECT/CT fusion images were processed

by 36 out of the 41 SPECT/CT performing responders (88%), and manual software fusion images were processed by 9 out of the 51 SPECT performing responders (18%). Details of the routine scan protocol were not associated with whether the responders were board-certified nuclear medicine technologists.

### Added imaging and omitted routine scan protocol

Three-quarters of the responders performed at least some additional imaging, whereas 16% omitted at least some scan element from their routine protocols. Most provided criteria for adding or omitting imaging based on decisions by technologists (Figure 2). The most added imaging was for pelvis SPECT, oblique thorax view, lateral head and neck view, head and neck SPECT, and lumbar SPECT (Table 3). The frequency of added

SPECT and SPECT/CT imaging was the highest in private hospitals (44%) and university hospitals (39%), respectively. Figure 3 shows the criteria used for added and omitted imaging, with 66% responding that they performed additional imaging because of the “presence of abnormal lesions”, 26% because of “change in the previous examination”, and 15% because of the “site of pain”. Evidence for the added imaging was mostly absent (7%), with much of the additional imaging performed based on experimental rules (42%). Some examples of justification of individual decisions for added imaging included “bladder covering the sacrum” and to “categorize as benign or malignant”. A few responders commented that they omitted some scans from their routine protocols when multiple bone metastases were present, or the bladder did not cover the sacrum.

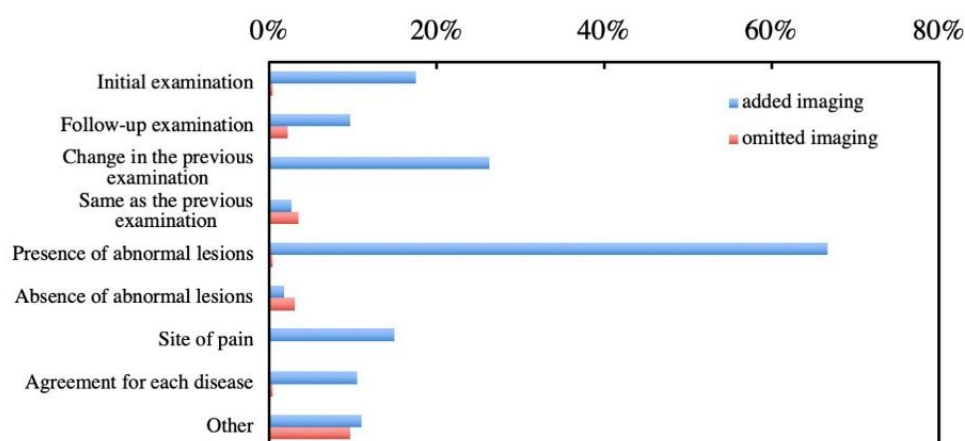


**Figure 2.** Responses to the question “How do you determine (a) additional or (b) omission imaging with your routine scan protocol?”  
UH, PuH, and PrH indicated university hospital (n=66), public hospital (n=86), and private hospital (n=72), respectively

**Table 3.** Body parts scanned and percentage of cases with respect to methods used for additional imaging

	Anterior view	Lateral view	Oblique view	SPECT	SPECT/CT	% Total
Head and neck	11	18	4	18	11	40
Thorax	3	4	18	16	7	38
Lumbar	4	3	6	17	9	30
Pelvis	4	4	9	22	12	32
Femoral	6	5	4	6	5	18
Spine and pelvis	0	0	0	8	4	12
Others	10	6	4	7	6	18

Abbreviations: CT, computed tomography; SPECT, single-photon emission computed tomography



**Figure 3.** Responses to the question “What are the criteria for additional or omission imaging with your routine scan protocol?”

## Discussion

This nationwide survey helps to clarify the state of bone scintigraphy practice in Japan. All 228 responders used routine scan protocols, but the methods used in those protocols varied markedly. Moreover, the frequency that routinely acquired SPECT and SPECT/CT were still not so high. In this survey, although the responders had access to SPECT/CT and SPECT systems (about 50% each), both modalities were underutilized. These findings indicate that bone scanning in Japan is gradually beginning to shift from reliance on planar whole-body imaging with additional spot planar images to the use of additional SPECT or SPECT/CT.

It was notable that routine bone scan protocols in Japan are beginning to diversify, but that only 40% of the responders routinely acquire SPECT or SPECT/CT imaging (Figure 1, Table 2). Furthermore, we found that  $\leq 30\%$  of the university hospitals obtained SPECT or SPECT/CT, and that only 14% and 20% of the responders obtained multi-field SPECT/CT and multi-field SPECT, respectively. Although SPECT/CT systems are available at approximately three-fourth of university hospitals, only one-fifth or less of university hospitals acquired SPECT/CT in routine protocol. In busy university hospitals, the frequency of added SPECT/CT imaging was the highest, and 30% of the responders had a consultation with a physician about added imaging in each case. This is despite many studies having described the enhanced diagnostic accuracy of multi-field SPECT/CT (8-10) and SPECT (5-7), particularly in prostate, breast, and lung cancer.

The lack of use of SPECT and SPECT/CT imaging may be attributable to four main reasons. First, SPECT acquisition prolongs the examination time to  $>10$  minutes per field (15), making the addition of SPECT or SPECT/CT a challenge in university hospitals wherein the number of examinations are

double that those at public or private hospitals (1). Second, the Japanese system of medical treatment fees provides that institutions can only charge for either a costly whole-body scan or a cheap SPECT but not for CT attenuation correction or localization. (i.e., added SPECT scanning cannot add to the costs of a whole-body bone scan.) Third, given that computer-assisted diagnosis in whole-body imaging can improve diagnostic accuracy (17-19), physicians and technologists in Japan might consider SPECT unnecessary. Fourth, acquiring bone SPECT/CT increases a person's exposure to radiation, which is about 2–5 mGy per field (9, 20). The responders indicated that the criteria for additional imaging were mostly experimental and based on few previous studies, suggesting that they had an incomplete knowledge of the diagnostic accuracies of SPECT/CT, SPECT, and planar whole-body images (5-15).

It is desirable to acquire additional localized SPECT or SPECT/CT in certain cases. For example, when localized lesions are present (21-23), SPECT/CT may help in differentiation between malignant and benign lesions (11, 15, 24); in the current study, 23% and 44% responders performed SPECT/CT and SPECT, respectively. There is also benefit in performing SPECT (including SPECT/CT) when patients report spinal or pelvic pain, even if the findings on whole-body images are normal (22, 23), as was done by 15% responders. Another relevant indication is when the level of prostate-specific antigen is increasing or is  $>20$  ng/mL (5, 16); however, this indication was not reported in this study. When the urinary bladder covers the sacrum (16), pelvis SPECT should be performed. Although the criteria are not clarified, additional pelvis SPECT were performed by 47% responders. Another 18% responders did not perform SPECT or SPECT/CT in routine scan protocol and additional imaging. Approximately half of these responders (8%) performed localized



planar imaging at least twice after whole-body scanning in the routine protocol.

Performing localized planar scans after whole-body scanning does not dramatically increase the diagnostic accuracy compared with SPECT because it has much lower contrast (25). In most cases in this study, the decision to perform additional imaging was made by a technologist (Figure 2a), suggesting that the accuracy in detecting bone metastases was more dependent on a technologist's knowledge. Replacing localized planar images with localized SPECT would serve to make the most of the limited examination time, especially when using rapid SPECT/CT scan techniques (26). The diagnostic accuracy of manually fused SPECT/CT is higher than that of SPECT (11). Using software to fuse images manually may further aid in increasing the diagnostic confidence when X-ray CT is performed. SPECT/CT images without scatter and attenuation correction are also useful for excluding misdiagnosis due to misalignment between the SPECT and CT images in combined SPECT/CT systems (27). In the current survey, only 18% responders reported using manual image fusing processes and only 3 out of the 41 SPECT/CT performing responders (7%) reported processing SPECT images without scatter and attenuation correction.

The omission of SPECT acquisition from routine scan protocols was uncommon, and typically reserved for cases where multiple bone metastases were present or where the bladder failed to cover the sacrum. However, it remains controversial whether SPECT/CT should be performed in patients with multiple bone metastases (8) or whether, indeed, SPECT/CT improves the detection of abnormal lesions when the bladder fails to cover the sacrum (9). The decision to omit SPECT requires careful judgment, with further study clearly required to determine the optimal criteria.

A limitation of this study is that the responses were obtained from different settings (e.g., medical institutions) and by responders with different certification standards (e.g., the percentage of board-certified nuclear medicine technologists). This was an unavoidable consequence of conducting the questionnaire among members of the Japanese Society of Radiological Technology. Moreover, because we did not inquire about the acquisition and reconstruction parameters used, we can offer no insights into the diagnostic performance of the various practice standards that were reported.

## Conclusion

In conclusion, this nationwide survey of the current state of bone scintigraphy in Japan shows

that SPECT and SPECT/CT are used infrequently in routine practice. Typically, these scans are added to whole-body scans only when abnormal lesions are detected. We therefore contend that these results provide the nuclear medicine technologists a better understanding of the current role of a bone scan protocol.

## Acknowledgement

We would like to sincerely thank everyone who responded to this survey. This study was performed with the support from a Japanese Society of Radiological Technology research grant (2017 and 2018).

## Conflict of Interest

The authors declare that they have no conflict of interest.

## Ethical approval

This article does not contain any studies with human participants or animals performed by any of the authors.

## References

1. The Present State of Nuclear Medicine Practice in Japan—A Report of the 8th Nationwide Survey in 2017. *Radioisotopes*. 2018; 67:339–87.
2. Sadik M, Suurkula M, Hoglund P, Jarund A, Edenbrandt L. Quality of planar whole-body bone scan interpretations a nationwide survey. *Eur J Nucl Med Mol Imaging*. 2008; 35:1464–72.
3. Sadik M, Suurkula M, Hoglund P, Jarund A, Edenbrandt L. Improved classifications of planar whole-body bone scans using a computer-assisted diagnosis system: a multicenter, multiple-reader, multiple-case study. *J Nucl Med*. 2009; 50:368–75.
4. Wesolowski CA, Yahil A, Puetter RC, Babyn PS, Gilday DL, Khan MZ. Improved lesion detection from spatially adaptive, minimally complex, Pixon reconstruction of planar scintigraphic images. *Comput Med Imaging Graph*. 2005; 29:65–81.
5. Einat ES, Ur M, Eyal M, Gennady L, Hedva L, Leibovitch I. The detection of bone metastases in patients with high-risk prostate cancer: 99mTc-MDP planar bone scintigraphy, single- and multi-field-of-view SPECT, 18F-fluoride PET, and 18F-fluoride PET/CT. *J Nucl Med*. 2006; 47:287–97.
6. Abikhzer GKG, Kagna O, Israel O, Frenkel A, Keidar Z. Whole-body bone SPECT in breast cancer patients: the future bone scan protocol? *Nucl Med Commun*. 2016; 37:247–53.
7. Schirrmester HGG, Glatting G, Hetzel J, Nussle K, Arslanemir C, Buck AK, et al. Prospective

- evaluation of the clinical value of planar bone scans, SPECT, and (18)F-labeled NaF PET in newly diagnosed lung cancer. *J Nucl Med.* 2001; 42:1800–804
8. Palmedo H, Marx C, Ebert A, Kreft B, Ko Y, Turler A, et al. Whole-body SPECT/CT for bone scintigraphy: diagnostic value and effect on patient management in oncological patients. *Eur J Nucl Med Mol Imaging.* 2014; 41:59–67.
  9. Rager O, Nkoulou R, Exquis N, Garibotto V, Tabouret-Viaud C, Zaidi H, et al. Whole-body SPECT/CT versus planar bone scan with targeted SPECT/CT for metastatic workup. *Biomed Res Int.* 2017; 2017:7039406.
  10. Lofgren J, Mortensen J, Rasmussen SH, Madsen C, Loft A, Hansen AE, et al. A prospective study comparing (99m) Tc-hydroxyethylene-diphosphonate planar bone scintigraphy and whole-body SPECT/CT with (18) F-fluoride PET/CT and (18) F-fluoride PET/MRI for diagnosing bone metastases. *J Nucl Med.* 2017; 58:1778–785.
  11. Utsunomiya D, Shiraishi S, Imuta M, Tomiguchi S, Kawanaka K, Morishita S, et al. Added value of SPECT/CT fusion in assessing suspected bone metastasis: comparison with scintigraphy alone and nonfused scintigraphy and CT. *Radiology.* 2006; 238:264–71.
  12. Sedonja I, Budihna NV. The benefit of SPECT when added to planar scintigraphy in patients with bone metastases in the spine. *Clin Nucl Med.* 1999; 24:407–13.
  13. Han LJ, Au-Yong TK, Tong WC, Chu KS, Szeto LT, Wong CP. Comparison of bone single-photon emission tomography and planar imaging in the detection of vertebral metastases in patients with back pain. *Eur J Nucl Med.* 1998; 25:635–38.
  14. Kosuda S, Kaji T, Yokoyama H, Yokokawa T, Katayama M, Iriye T, et al. Does bone SPECT actually have lower sensitivity for detecting vertebral metastasis than MRI? *J Nucl Med.* 1996; 37:975–78.
  15. Reinartz P, Schaffeldt J, Sabri O, Zimny M, Nowak B, Ostwald E, et al. Benign versus malignant osseous lesions in the lumbar vertebrae: differentiation by means of bone SPET. *Eur J Nucl Med.* 2000; 27:721–26.
  16. Shafi A, Thorsson O, Edenbrandt L. New routine for nuclear medicine technologists to determine when to add SPECT/CT to a whole-body bone scan. *J Nucl Med Technol.* 2014; 42:28–32.
  17. Horikoshi H, Kikuchi A, Onoguchi M, Sjostrand K, Edenbrandt L. Computer-aided diagnosis system for bone scintigrams from Japanese patients: importance of training database. *Ann Nucl Med.* 2012; 26:622–26.
  18. Sadik M, Hamadeh I, Nordblom P, Suurkula M, Hoglund P, Ohlsson M, et al. Computer-assisted interpretation of planar whole-body bone scans. *J Nucl Med.* 2008; 49:1958–65.
  19. Takahashi Y, Yoshimura M, Suzuki K, Hashimoto T, Hirose H, Uchida K, et al. Assessment of bone scans in advanced prostate carcinoma using fully automated and semi-automated bone scan index methods. *Ann Nucl Med.* 2012; 26:586–93.
  20. Iball GR, Bebbington NA, Burniston M, Edyvean S, Fraser L, Julyan P, et al. A national survey of computed tomography doses in hybrid PET-CT and SPECT-CT examinations in the UK. *Nucl Med Commun.* 2017; 38:459–70.
  21. Iqbal B, Currie GM, Wheat JM, Raza H, Kiat H. The incremental value of SPECT/CT in characterizing solitary spine lesions. *J Nucl Med Technol.* 2011; 39:201–7.
  22. De Maeseneer M, Lenchik L, Everaert H, Marcelis S, Bossuyt A, Osteaux M, et al. Evaluation of lower back pain with bone scintigraphy and SPECT. *Radiographics.* 1999; 19:901–12.
  23. Delpassand ES Jr G, Bhadkamkar V, Podoloff DA. Value of SPECT imaging of the thoracolumbar spine in cancer patients. *Clin Nucl Med.* 1995; 20:1047–51.
  24. Horger M, Eschmann SM, Pfannenberger C, Vonthein R, Besenfelder H, Claussen CD, et al. Evaluation of combined transmission and emission tomography for classification of skeletal lesions. *AJR* 2004; 183:655–61.
  25. Ichikawa H, Kato T, Shimada H, Watanabe Y, Miwa K, Matsutomo N, et al. Detectability of thoracic bone scintigraphy evaluated using a novel custom-designed phantom. *Jpn J Nucl Med Technol.* 2017; 37:229–38.
  26. Zacho HD, Manresa JAB, Aleksyniene R, Ejlersen JA, Fledelius J, Bertelsen H, et al. Three-minute SPECT/CT is sufficient for the assessment of bone metastasis as add-on to planar bone scintigraphy: prospective head-to-head comparison to 11-min SPECT/CT. *EJNMMI Res.* 2017; 7:1.
  27. Van den Wyngaert T, Strobel K, KampenWU, Kuwert T, van der Bruggen W, Mohan HK, et al. The EANM practice guidelines for bone scintigraphy. *Eur J Nucl Med Mol Imaging.* 2016; 43:1723–38.