

# Feasibility of shortened scan acquisition time with IQ-SPECT technology using SMARTZOOM(TM) collimator in myocardial perfusion imaging

Saranya Thiruvengadam, Dinesh Kumar Gauthaman, Nikita Sampathirao, Indirani Elangovan, Shelley Simon\*

Department of Nuclear Medicine, Apollo Hospitals, Chennai, India

## ARTICLE INFO

Article type:  
Original Article

Article history:  
Received: 15 Feb 2024  
Revised: 4 Oct 2024  
Accepted: 23 Feb 2025

Keywords:  
IQ-SPECT  
Cardiac-specific SMARTZOOM  
(TM) collimator  
Myocardial perfusion imaging  
Shorter acquisition time  
Image quality

## ABSTRACT

**Objective(s):** IQ-SPECT technology uses cardiac-specific SMARTZOOM(TM) collimator that can reduce the time required to acquire myocardial perfusion images to half (14 seconds/view) of a standard SPECT procedure. This study aimed to further shorten the scan acquisition time (7 seconds/view) using the SMARTZOOM(TM) collimator without compromising the image quality.

**Methods:** This prospective observational study involved 50 patients (39 men and 11 women) who underwent myocardial perfusion studies using the SMARTZOOM(TM) collimator. The scans were acquired in 7 seconds/view (Group A) and 14 seconds/view (Group B). Attenuation-corrected (AC), non-attenuation-corrected (NAC), and polar maps were generated for both groups using the QGS/QPS software. The groups were qualitatively and quantitatively compared in terms of image quality, relative uptake score, summed scores, total perfusion deficit, and left ventricular ejection fraction (LVEF).

**Results:** The image quality of both groups was comparable in the AC studies, whereas Group B was superior to Group A in the NAC studies. All images exhibited an image quality score of  $\geq 3$ , which suggested adequate image quality. The mean LVEF values were 62.16 and 64.34 in Groups A and B, respectively (p-value 0.326). A strong positive correlation was observed between the two datasets (Pearson's  $r=0.59$ ). The mean summed score in the AC images was 7.5 in both groups (p-value 0.49), and in the NAC images, the scores were 7.68 in Group A and 7.46 in Group B (p-value 0.46). The mean total perfusion deficits calculated using the 17-segment models were 11% and 16% in Group A and Group B, respectively, for the AC images (p-value 0.143) and 11.2% and 16.5% in Group A and Group B, respectively, for the NAC images (p-value 0.135). Significant differences were not noted in the calculation of the relative uptake score in segments 1–17 for the AC and NAC images in Groups A and B.

**Conclusion:** The findings from this study indicate that further shortening of the scan acquisition time to 7 seconds/view is possible in myocardial perfusion imaging using the SMARTZOOM(TM) collimator without compromising the scan quality and the results, thus improving patient comfort.

► Please cite this paper as:

Thiruvengadam S, Gauthaman DK, Sampathirao N, Elangovan I, Simon Sh. Feasibility of shortened scan acquisition time with IQ-SPECT technology using SMARTZOOM(TM) collimator in myocardial perfusion imaging. Asia Ocean J Nucl Med Biol. 2025; 13(2): 138-145. doi: 10.22038/aojnmb.2025.78149.1551

## Introduction

Myocardial perfusion SPECT imaging is routinely performed in most nuclear medicine departments globally. Cardiac nuclear imaging has evolved over the years, with modern advances in imaging equipment, techniques, and

protocols to produce excellent-quality images. Qualitative and quantitative analysis of the information thus obtained can be used to diagnose a broad spectrum of cardiac diseases (1). A major utility of myocardial perfusion imaging (MPI) is the evaluation of widely prevalent

\* Corresponding author: Shelley Simon. Department of Nuclear Medicine, Apollo Hospitals, Greaves Road, Greaves Lane, Chennai, Tamil Nadu – 600006, India. Tel: 9884055655; E-mail: shelleyssimon@rediffmail.com

© 2025 mums.ac.ir All rights reserved.

This is an Open Access article distributed under the terms of the Creative Commons Attribution License (<http://creativecommons.org/licenses/by/3.0>), which permits unrestricted use, distribution, and reproduction in any medium, provided the original work is properly cited.

coronary artery disease (CAD). The ability of this technique to reflect myocardial perfusion during rest and stress and the wide range of quantitative data acquired from the gating of the study have made it a convenient diagnostic modality that is readily available and helps clinicians in making decisions in the management of CAD.

A significant development in MPI is the advancement in hardware technology. Highly sensitive detectors and cardiac-specific dedicated collimators with a geometry focused on the heart and capturing four times more counts than the conventional low-energy high-resolution (LEHR) parallel hole collimators are now available (2). Conventional parallel whole collimators are not ideal for small organs as they require a prolonged scan time and also high injected doses to acquire an optimum number of counts for good image quality. Furthermore, multiple factors such as detector motion, size and shape of the collimator holes, deflections of the gantry, and distance between

the patient and the detector affect the overall image quality. In addition, the rotational movement of the gantry with the detectors in close proximity to the patient for a long duration might be an additional factor of concern in those with claustrophobia.

Cardiac-specific collimators have been introduced, which have improved the acquisition as well as the image quality in MPI. IQ-SPECT technology (Siemens Medical Solutions USA, Inc., Hoffman Estates, IL, USA) uses cardiac specific SMARTZOOM(TM) collimator, which has a combination of a converging collimator at the center and a parallel-hole collimator at the periphery (Figure 1). This technology possesses three critical qualities, which include smart zoom collimation, cardio-centric orbit, and special iterative reconstruction methods. The addition of an SMARTZOOM(TM) collimator has shortened the acquisition time, producing an image of higher quality and resolution than the routinely used LEHR collimators (3).



**Figure 1.** SMARTZOOM(TM) collimator – cardio-centric orbit  
Configuration of SMARTZOOM(TM) collimator with converging collimator at the centre and parallel whole collimator at the periphery

The standard acquisition time of MPI with the LEHR collimator is approximately 16 minutes (32 views, with 30 seconds per view). In contrast, acquisition with the SMARTZOOM (TM) collimator is shorter, with a duration of 4 minutes (17 stops per detector at 14 seconds per stop). The image quality is comparable, and the SMARTZOOM(TM) collimator exhibits the added advantages of faster acquisition and higher sensitivity (4). However, even a 4- minute

duration of imaging might be uncomfortable for certain patients because of the prolonged positioning of hands above the head, especially for those with claustrophobia and musculoskeletal disorders. Thus, this study aimed to shorten the scan acquisition time further using the SMARTZOOM(TM) collimator for MPI without compromising the image quality and attempted to analyze the effects of shortening the time per stop to 7 seconds.

## Methods

A prospective observational study was conducted in the Department of Nuclear Medicine, Apollo Hospitals, Chennai, over a period of 2 years from 2019 to 2022. This study involved 50 participants (39 men and 11 women) in the age group of 39–81 years (mean age 56.32 years). Patients referred to MPI for the evaluation of CAD were included in the study. Patients who were reluctant to lie down for a long duration (for two scans) were excluded. Patients with bariatric issues who had a body mass index of  $\geq 30$  were not included in the study as the standard dose and a scan acquisition time of 8 minutes are recommended by the manufacturer (SIEMENS) for this patient subgroup. This study was approved by the institutional review board, and written informed consent for participation in the study was obtained from all patients. The patients were instructed to observe 2 hours of fasting before the procedure.

Rest and stress MPI were performed under a 22-day protocol. The mode of stress (physical or pharmacological) was decided by the nuclear medicine physicians as indicated. A single

injection of 10–12 mCi (370–444 MBq) Tc-99m MIBI was administered intravenously at rest and peak stress (5). Milk-based fat-rich blend, which was prepared in-house, was given to the patients post-injection to enhance the hepatic clearance of the tracer. MPI was performed at 60–90 minutes post-injection in a dual-headed gamma camera with cardiac-specific SMART ZOOM(TM) collimators (IQ-SPECT, Symbia T6, SIEMENS healthcare). The manufacturer's recommendation for MPI acquisition using the SMARTZOOM(TM) collimator in a dual-headed gamma camera is 17 stops per detector at 14 seconds per stop, thus resulting in a total of 34 projections acquired in 4 minutes.

The participants underwent rest and stress MPI scan acquisitions in a dual-headed gamma camera with the SMARTZOOM(TM) collimator—each with half the recommended acquisition time (7 seconds per stop) as well as the standard acquisition time (14 seconds per stop). Thus, two rest and two stress MPI studies were acquired for each patient (6–8). The image acquisition parameters are listed in Table 1. A low-dose CT acquisition for attenuation correction followed the SPECT acquisition.

**Table 1.** Acquisition parameters for MPI

Position of the detectors	76°
Collimator type	SMARTZOOM(TM) collimator
Angle of rotation	104°
Stops/Views	17 per detector
Duration per stop	7 seconds and 14 seconds
Matrix size	64×64
Reconstruction algorithm	Iterative Flash 3D
Position of the patient	Supine
ECG gating	Gate bin 8
Number of frames	8

The MPI raw data were processed using the Cedar Sinai software. After reconstruction, the images were reproduced in three axes—short axis, vertical long axis, and horizontal long axis—and analyzed both qualitatively (visual inspection based on the color scale) and quantitatively using automatic quantification, i.e., quantitative-gated and perfusion SPECT (QGS/QPS). Polar maps with 17 segments were generated for the perfusion analysis. Gated images were used to analyze the left ventricular wall motion and thickening for all scans.

The rest and stress image datasets of the study population were categorized into two groups, Group A (7 seconds) and Group B (14 seconds), and were scrutinized with respect to image

quality, relative uptake score, summed scores, and total perfusion deficit (TPD). Furthermore, the left ventricular ejection fraction (LVEF) was compared between the two groups for the quantitative assessment (9, 10).

### Image quality scoring

Two experienced nuclear medicine physicians assessed the image quality using the 17-segment cardiac model of the American Society of Nuclear Cardiology (ASNC). For subjective evaluation of the image appearance (Table 2) between the two groups, an ordinal score of 1–5 was assigned for each entire image set of the left ventricular myocardium.

**Table 2.** Image quality score

Image quality score	
1	Very poor
2	Poor
3	Adequate
4	Good
5	Very good

### Relative uptake scoring

The scores given by the software for the relative activity in each segment of the

myocardium compared with the images of the normal database (11) are presented in Table 3.

**Table 3.** Relative uptake score

Relative uptake score	
0	Normal perfusion
1	Mild reduction in counts but definitely not abnormal
2	Moderate reduction in counts and definitely abnormal
3	Severe reduction in counts
4	Absent tracer uptake

Statistical analysis was performed using SPSS (Statistical Package for the Social Sciences) version 18.0.

### Camera parameter settings for IQ-SPECT with SMARTZOOM(TM) collimator

Zoom: 1.0; Matrix 64×64; 17 views per detector obtained at 7 seconds and 14 seconds per view. A scanning arc of 104° over angular steps of 6° was used for each of the camera heads.

The rotation was restricted to 104° to keep the heart 28 cm from the camera surface throughout the acquisition to maximize the sensitivity. The ECG gating threshold was 20%, and the gate bin used was 8. Gated at 8 frames per cardiac cycle, neither attenuation nor scatter correction was applied.

Cedars Sinai QGS and QPS analysis: The reconstruction was performed using the Flash 3-dimensional ordered subset conjugate gradient minimize (3D OSCGM) algorithm, 30 iterations with 1 subset, and a Gaussian filter with a full-width half maximum (FWHM) of 14 mm.

Both attenuation and scatter correction were applied for Tc-99m. Both acquisitions were obtained for all participants (7 seconds/14 seconds).

## Results

Group A and Group B images were compared in terms of LVEF, summed scores, TPD, relative uptake score, and image quality. Pearson values were analyzed for quantitative and qualitative assessment in both groups. A p-value of <0.05 was considered statistically significant.

### LVEF

The comparison of LVEF between Groups A (7-second images) and B (14-second images) did not show any significant difference between the two datasets. The mean LVEF values were 62.16 and 64.34 in Group A (7-second images) and Group B (14-second images), respectively (p-value 0.326). A strong positive correlation was observed between the two datasets (Pearson's  $r = 0.59$ ).

### Summed scores

The total summed score was calculated for the left ventricular myocardium at rest and stress for each group. Significant differences were not noted in the summed scores between the two groups. The mean summed score for attenuation-corrected (AC) images was 7.5 in Group A and Group B (p-value 0.49), and those for non-attenuation-corrected (NAC) images were 7.68 in Group A and 7.46 in Group B (p-value 0.46).

### TPD

The TPDs for both groups were calculated according to the 17-segment cardiac model of the ASNC guidelines in both AC and NAC studies. Significant differences were not perceived between the two groups in both AC and NAC images. The mean TPDs were 11% and 16% in Groups A and B, respectively, for AC images (p-value 0.143) and 11.2% and 16.5% in Groups A and B, respectively, for NAC images (p-value 0.135).

A strong correlation was observed between Groups A and B in the calculation of TPD using the AC and NAC images (AC Pearson  $r=1$ ; NAC Pearson's  $r=1$ ).

### Relative uptake score

The calculation of the relative uptake score in segments 1–17 for AC and NAC images in Groups A and B did not show significant differences.

### Image quality

The counts per frame were in the range of 24000–27000 for Group A (7 seconds) and 48000–52000 for Group B (14 seconds). Both Group A (7 seconds) and Group B (14 seconds) images were of comparable quality in the AC studies, whereas Group B was superior to Group A in the NAC images. However, all images had an image quality score of  $\geq 3$ , which suggested adequate overall image quality.

Thus, the use of the IQ-SPECT technology with SMARTZOOM(TM) collimator, cardio-centric orbit, iterative reconstruction method, and CT-



based attenuation correction could reduce the acquisition time while maintaining comparable image quality.

## Discussion

IQ-SPECT technology has a high-efficiency multi-cone focal SMARTZOOM(TM) collimator, cardio-centric orbit, iterative reconstruction, and scatter correction. These notable features aid in achieving better scan quality with shorter acquisition time in MPI when compared with the LEHR collimator (12). Hence, further reduction of acquisition time from 14 seconds per view to 7 seconds per view is feasible with IQ-SPECT technology.

Leva L et al. conducted a comparative study in patients who had undergone MPI using both LEHR and SMARTZOOM(TM) collimators regarding the tolerance and comfort levels. The findings indicated that patients were more comfortable with studies done in SMARTZOOM(TM) collimators than in LEHR collimators as the acquisition time was reduced by half (13). The acquisition times per angular step of the detector using SMARTZOOM(TM) collimators were 14 and 28 seconds/view in their study. In this study, the feasibility of further reducing the acquisition time to half using SMARTZOOM(TM) collimators (i.e., 7

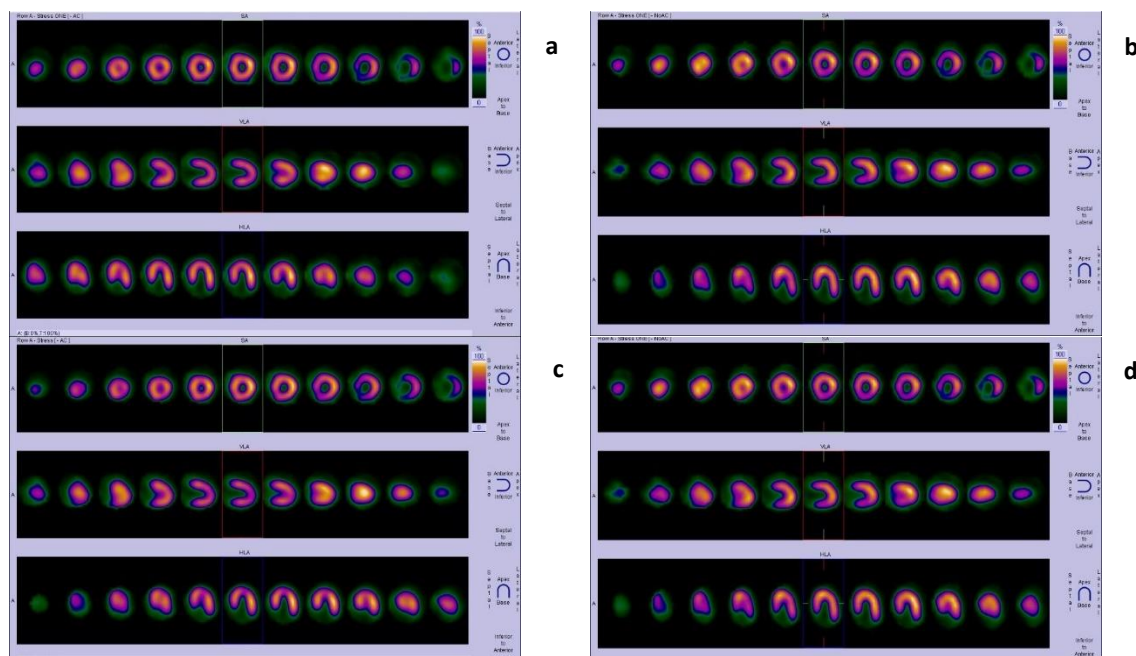
seconds/view) without compromising the image quality to improve patient comfort was analyzed.

Parameters such as image quality, LVEF, summed score, TPD, and relative uptake score were used as standards to compare the images acquired in 7 seconds per view (Group A) and 14 seconds per view (Group B) using the SMARTZOOM(TM) collimator.

Caobelli et al. compared myocardial perfusion studies performed using IQ-SPECT technology in 6 seconds per view and 12 seconds per view and concluded that the image quality was reduced in case of shorter acquisition time (7).

However, our findings indicated comparable image quality between studies done in 7 seconds per view and 14 seconds per view in AC. All images exhibited quality scores of  $\geq 3$ , which suggests adequate overall image quality.

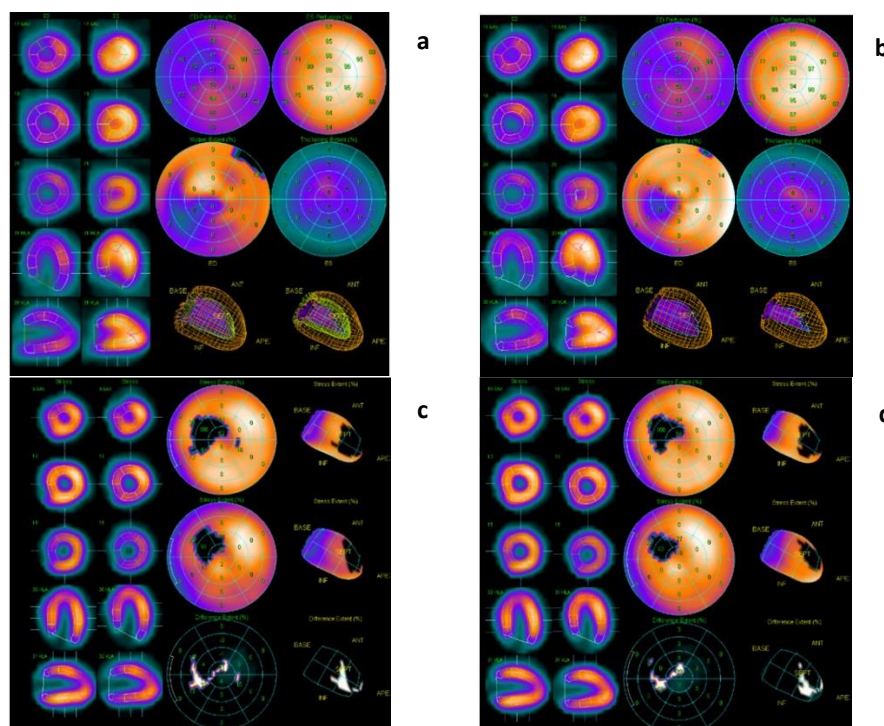
In this study, no significant difference was observed in the summed score results, TPD, or LV volume between the studies done in 7 seconds per view and 14 seconds per view. Moreover, a strong positive correlation was observed in the LVEF between the studies done in 7 seconds per view and those done in 14 seconds per view (representative images: Figures 2 and 3).



**Figure 2.** 52-year-old male with diabetes, recently detected coronary artery disease, 70% stenosis in left anterior descending artery (LAD), was referred for myocardial perfusion imaging to assess the provokable ischemia in LAD territory. Both rest and physical stress myocardial perfusion studies were performed. Attenuation-corrected (AC) and non-attenuation-corrected (NAC) stress images were reconstructed in both 7 seconds and 14 seconds per view (Figures a, b, c and d, respectively) (a) 7 seconds AC image, (b) 7 seconds NAC image, (c) 14 seconds AC image, (d) 14 seconds NAC images

All the images (Figures 2a, 2b, 2c and 2d) were of comparable quality. The qualitative and quantitative comparison parameters in both groups A and B were as follows:

	Group A		Group B	
	AC images	NAC images	AC images	NAC images
Image quality score	5	5	5	5
Relative uptake score	0	0	0	0
Summed stress score	0	0	0	0
TPD	0	0	0	0
LVEF	66		67	



**Figure 3.** A 48-year-old male with a history of acute myocardial infarction, Triple vessel disease, post PTCA to left anterior descending artery (LAD) was referred for myocardial perfusion imaging 3 months later to assess provokable ischemia in left circumflex (LCx) and right coronary artery (RCA) territories. Both rest and physical stress myocardial perfusion studies were performed. Stress study was reconstructed in both 7 seconds and 14 seconds per view using the automatic quantification QGS and QPS (Figures a, b, c and d, respectively). Polar maps with 17 segments were generated for the perfusion analysis. (a) QGS 7 seconds/ view, (b) QGS 14 seconds/ view, (c) QPS 7 seconds/ view, (d) QPS 14 seconds/ view

All the images (Figures 3a, 3b, 3c and 3d) were of comparable quality. The qualitative and quantitative comparison parameters in both group A and B were as follow:

	QGS		QPS	
	Group A	Group B	Group A	Group B
Image quality score	5	5	5	5
Summed stress score			11	11
TPD			10	8
LVEF	69	70		

Our study, therefore, demonstrated a strong correlation in parameters such as image quality, TPD, summed score, and LVEF using SMARTZOOM(TM) collimator with a standard dose and shortened acquisition time. This could be attributed to the collimator's indigenous ability to magnify the center of the field of view (i.e., the heart in the myocardial perfusion study) while avoiding truncation from the periphery.

**1. SMARTZOOM(TM) collimator:** The focus of the collimator varies continuously from cone-

like geometry in the center to parallel geometry toward the periphery, thus providing magnification of the cardiac region while avoiding the truncation of the surrounding tissue. Unlike conventional large-bore, parallel-hole collimators, the SMARTZOOM(TM) collimator achieves a gain in counts without compromising the image resolution, reducing the imaging time considerably.

**2. Cardio-centric acquisition:** IQ-SPECT technology is superior to conventional scan acquisition owing to its software-assisted

flexible gantry motion feature. The cardio-centric orbit allows the detectors to rotate around a virtual center of rotation positioned over the heart. The characteristic features of this centric acquisition are the relative detector position, the radius of rotation, and the arc used to acquire images of the heart from all view angles. These characteristics aid in increasing the sensitivity and resolution.

**3. Reconstruction:** IQ-SPECT reconstruction includes the geometry of SMARTZOOM(TM) collimators, cardio-centric orbit of the detectors, and ordered subset expectation maximization reconstruction. This reconstruction technique also comprises state-of-the-art distance-dependent isotropic 3D resolution recovery and ordered subset conjugate gradient minimizer (14).

## Conclusion

A 7-second per view acquisition is possible in MPI and has image quality similar to a 14-second per view acquisition using the SMARTZOOM(TM) collimator in IQ-SPECT technology. Thus, IQ-SPECT technology enables the acquisition of comparable-quality scans in a shorter time with a standard dose to assess TPD, summed score, and LVEF without the loss of any diagnostic information. Faster scan acquisition is possible, thus reducing the waiting time of patients, increasing the department's efficiency, and streamlining the workload. In addition, scan acquisition can be performed with ease in patients having claustrophobia and debilitating conditions without compromising their comfort.

## References

1. Erwin WD, Jessop AC, Mar MV, Macapinlac HA, Mawlawi OR. Qualitative and quantitative comparison of gated blood pool single photon emission computed tomography using low-energy high-resolution and SMARTZOOM(TM) collimation. *Nuclear medicine communications*. 2017; 38(1): 35-43.
2. Du Y, Bhattacharya M, Frey EC. Simultaneous Tc-99m/I-123 dual-radionuclide myocardial perfusion/ innervation imaging using Siemens IQ-SPECT with SMARTZOOM(TM) collimator. *Physics in Medicine & Biology*. 2014; 59(11): 2813.
3. Horiguchi Y, Ueda T, Shiomori T, Kanna M, Matsushita H, Kawaminami T, Sudo Y, Kikuchi S, Sasaki R, Hoshimiya J, Morita Y. Validation of a short-scan-time imaging protocol for thallium-201 myocardial SPECT with a multifocal collimator. *Annals of nuclear medicine*. 2014; 28: 707-15.
4. Pirich C, Keinrath P, Barth G, Rendl G, Rettenbacher L, Rodrigues M. Diagnostic accuracy and functional parameters of myocardial perfusion scintigraphy using accelerated cardiac acquisition with IQ SPECT technique in comparison to conventional imaging. *The Quarterly Journal of Nuclear Medicine and Molecular Imaging*. 2017; 61(1): 102-107.
5. Lyon MC, Foster C, Ding X, Dorbala S, Spence D, Bhattacharya M, et al. Dose reduction in half-time myocardial perfusion SPECT-CT with multifocal collimation. *Journal of Nuclear Cardiology*. 2016; 23(4): 657-67.
6. Caobelli F, Kaiser SR, Thackeray JT, Bengel FM, Chieragato M, Soffientini A, et al. The importance of a correct positioning of the heart using IQ-SPECT system with multifocal collimators in myocardial perfusion imaging: a phantom study. *Journal of Nuclear Cardiology*. 2015; 22(1): 57-65.
7. Einstein AJ, Blankstein R, Andrews H, Fish M, Padgett R, Hayes SW, et al. Comparison of image quality, myocardial perfusion, and left ventricular function between standard imaging and single-injection ultra-low-dose imaging using a high-efficiency SPECT camera: the MILLISIEVERT study. *Journal of Nuclear Medicine*. 2014; 55(9): 1430-7.
8. Hippeläinen E, Mäkelä T, Kaasalainen T, Kaleva E. Ejection fraction in myocardial perfusion imaging assessed with a dynamic phantom: comparison between IQ-SPECT and LEHR. *EJNMMI physics*. 2017; 4(1):1-4.
9. Abbott BG, Case JA, Dorbala S, Einstein AJ, Galt JR, Pagnanelli R, et al. Contemporary cardiac SPECT imaging—innovations and best practices: an information statement from the American society of nuclear cardiology. *Circulation: Cardiovascular Imaging*. 2018; 11(9): e000020.
10. Caobelli F, Thackeray JT, Soffientini A, Bengel FM, Pizzocaro C, Guerra UP. Feasibility of one-eighth time gated myocardial perfusion SPECT functional imaging using IQ-SPECT. *European journal of nuclear medicine and molecular imaging*. 2015; 42: 1920-8.
11. Doğan C, Çınaral F, Karagöz A, Bayram Z, Önal SÇ, Candan Ö, et al. Comparison of automated quantification and semi quantitative visual analysis findings of IQ SPECT MPI with conventional coronary angiography in patients with stable angina. *Türk Kardiyol Dern Ars*. 2019; 47(5): 357-64.
12. Joergensen T, Hansson SH. Evaluation of the left ventricular ejection fraction with gated IQ-SPECT myocardial perfusion imaging.

- Journal of Nuclear Medicine Technology. 2015; 43(3): 193-200.
13. Leva L, Matheoud R, Sacchetti G, Carriero A, Brambilla M. Agreement between left ventricular ejection fraction assessed in patients with gated IQ-SPECT and conventional imaging. *Journal of Nuclear Cardiology*. 2020; 27(5): 1714-24.
  14. Caobelli F, Kaiser SR, Thackeray JT, Bengel FM, Chiericato M, Soffientini A, et al. IQ SPECT allows a significant reduction in administered dose and acquisition time for myocardial perfusion imaging: evidence from a phantom study. *Journal of Nuclear Medicine*. 2014; 55(12): 2064-70.