

A Case of Ewing Sarcoma of the Mandible on ^{18}F -FDG PET/CT

Yasukage Takami^{1*}, Fumitoshi Aga¹, Katsuya Mitamura¹, Takashi Norikane¹, Hanae Okuda¹, Yuka Yamamoto¹, Minoru Miyake², Yoshihiro Nishiyama¹

¹ Department of Radiology, Faculty of Medicine, Kagawa University, Japan

² Department of Oral and Maxillofacial Surgery, Faculty of Medicine, Kagawa University, Japan

ARTICLE INFO

Article type:

Case report

Article history:

Received: 15 Mar 2019

Revised: 26 Jul 2019

Accepted: 30 Jul 2019

Keywords:

^{18}F -FDG

PET/CT

Ewing sarcoma

Mandible

ABSTRACT

Ewing Sarcoma is the second most common type of bone cancer in children. The dominant features of this malignant bone tumor are the tendency for rapid growth and metastasis. In addition, Ewing sarcoma of the mandible is extremely rare and can be mistaken for odontogenic infection. We report a 14-year-old girl who had had swelling, pain, and hypoesthesia in the left cheek for three weeks. She was diagnosed with pericoronitis initially, and then referred to our hospital due to worsening symptoms. CT and MRI revealed an expanding and destructive mass mainly in the left mandible. ^{18}F -fluorodeoxyglucose (^{18}F -FDG) positron emission tomography (PET) and fused PET/CT demonstrated increased uptake in the mandibular lesion. Whole-body ^{18}F -FDG PET images showed no abnormal activity except for the mandibular lesion. Histologic examination confirmed Ewing sarcoma. Although this tumor has an aggressive clinical behavior and rapid growth, early diagnosis can reduce patient's morbidity, mortality and thus it is important to distinguish it from periodontal inflammation.

►Please cite this paper as:

Takami Y, Aga F, Mitamura K, Norikane T, Okuda H, Yamamoto Y, Miyake M, Nishiyama Y. A Case of Ewing Sarcoma of the Mandible on ^{18}F -FDG PET/CT. Asia Ocean J Nucl Med Biol. 2020; 8(1):84-87. doi: 10.22038/aojnmb.2019.13876

Introduction

Ewing sarcoma is the second most common primary bone cancer in children (1). Although Ewing sarcoma can occur in any part of skeleton, the most frequent locations are the long bones (58%), pelvis (20%) and ribs (7%) (2). The occurrence of Ewing sarcoma in the mandible is extremely rare (0.7% of all sites) (2). In the mandibular lesion, clinical symptoms such as swelling, pain and sensory disturbances are unspecific and can sometimes lead to misdiagnosis (3-6).

In addition, rapid growth and a tendency for metastasis are the dominant features of Ewing sarcoma; thus, mandibular involvement may be due to metastasis from another skeletal site (7). Several studies have demonstrated the usefulness of ^{18}F -fluorodeoxyglucose (^{18}F -FDG) PET/CT for

staging, restaging and recurrence monitoring of Ewing sarcoma (8-9). Most case reports on Ewing sarcoma, involving the mandible have focused on the plain radiologic features, CT, and MRI. There are few descriptions of the findings of ^{18}F -FDG PET/CT.

Here, we reported a case of a patient with Ewing sarcoma undergoing ^{18}F -FDG PET/CT, with increased uptake in the mandibular mass.

Case report

A 14-year-old girl who had swelling, pain, and hypoesthesia in the left cheek for three weeks. She was diagnosed with pericoronitis initially, and then referred to our hospital due to worsening symptoms. Blood examination showed slightly elevated CRP (0.22 mg/dl). CT image showed an expansile lytic lesion in the mandible (Figure 1).

* Corresponding author: Yasukage Takami. Department of Radiology, Faculty of Medicine, Kagawa University, 1750-1 Ikenobe, Miki-cho, Kita-gun, Kagawa 761-0793, Japan. Tel: +81-87-891-2219; Fax+81-87-891-2220; Email: ytakami@med.kagawa-u.ac.jp

© 2020 mums.ac.ir All rights reserved.

This is an Open Access article distributed under the terms of the Creative Commons Attribution License (<http://creativecommons.org/licenses/by/3.0>), which permits unrestricted use, distribution, and reproduction in any medium, provided the original work is properly cited.

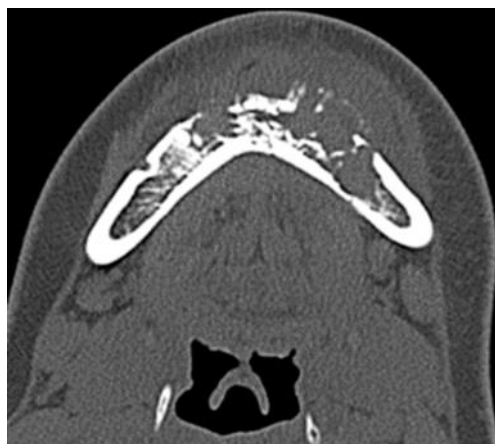

Figure 1. The bone window CT image shows a destruction of mandible

MRI images revealed destructive bone lesions with extension to the adjacent soft tissue mainly in the left mandible (Figure 2). ^{18}F -FDG PET/CT was subsequently performed to evaluate distant metastasis. ^{18}F -FDG PET and fused PET/CT images

showed increased uptake in the mandibular mass ($\text{SUV}_{\text{max}}=7.79$) (Figure 3). Whole-body ^{18}F -FDG PET images showed no abnormal activity except for the mandibular lesion (Figure 3).

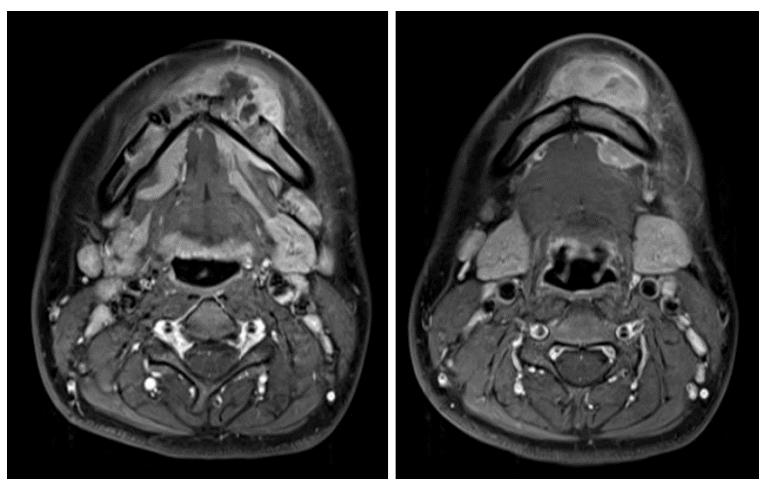


Figure 2. Transverse T1-weighted post contrast MR images reveal a destructive mandible lesion with extension to the adjacent soft tissue with inhomogeneous enhancement

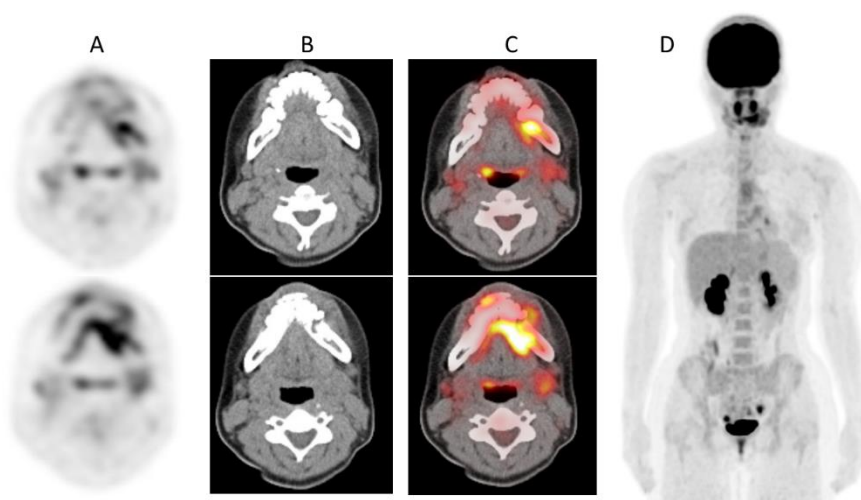


Figure 3. Transverse ^{18}F -FDG PET (A), CT (B), and PET/CT fused (C) images show increased uptake in the tumor ($\text{SUV}_{\text{max}}=7.79$). ^{18}F -FDG PET maximum intensity projection image (D) reveals no other abnormal uptake suggestive of metastasis

In this study, an incisional biopsy was performed. Histologic examination revealed a proliferation of small round to oval cells having hyperchromatic nuclei and scant cytoplasm, arranged in sheet-like patterns. Immunohistochemistry showed positive for CD99 (Figure 4), but negative for CD3, CD20, TdT and desmin. Reverse transcription-polymerase chain reaction analysis identified an Ewing sarcoma breakpoint region 1-ETS-related gene (EWSR1-ERG) fusion transcripts. The pathological findings indicated the diagnosis of Ewing sarcoma.

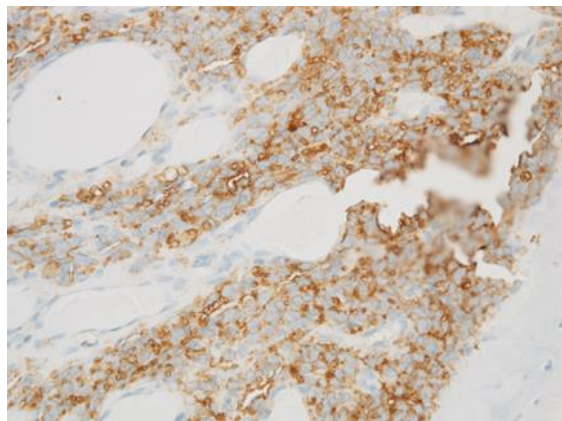


Figure 4. The tumor cells show strong membrane-staining pattern for CD99

Discussion

Ewing sarcoma, which is very rare in the mandible, occurs most frequently in long bones (2) (2). Swelling, pain, and paresthesia may be first manifestations of Ewing sarcoma of the oral cavity, occurring also in dental infections (10). Therefore, Ewing sarcoma involving mandible case is often misdiagnosed as periodontal inflammation (6). In the present case, the patient was initially diagnosed with pericoronitis.

The general radiologic appearance of Ewing sarcoma is a mass accompanied by the destruction of bone (11). CT and MRI have been considered as the best imaging methods for evaluating the tumor (12). MRI is widely accepted as the imaging method for evaluation of the extent of the primary lesion. In this study, the mass was detected by MRI, and suggested the possibility of malignant pathology. However, it is difficult to distinguish Ewing sarcoma of the mandible from other mandibular tumors in children, such as osteosarcoma, rhabdomyosarcoma, malignant lymphoma, and metastatic carcinoma.

The present case showed the value of ^{18}F -FDG PET/CT for staging of Ewing sarcoma in the mandible. Gupta et al. reported that the primary Ewing sarcoma family of tumors in patients with metastasis (mean $\text{SUV}_{\text{max}}=11.31$) showed significantly a higher glucose metabolism than

that in patients without metastasis (mean $\text{SUV}_{\text{max}}=6.84$) (13). Conventional staging evaluation for Ewing sarcoma includes imaging of the primary tumor (typically with MRI), as well as imaging of the lungs with chest CT, bone scintigraphy to screen for bone metastasis, and bone marrow biopsies and aspirates (14). Recently, the use of ^{18}F -FDG PET/CT to screen bone, soft tissue, and bone marrow metastases has been increasingly incorporated into the initial staging of the disease, as well as into surveillance both during and following completion of therapy (15).

Ewing sarcoma is a radiosensitive tumor. Multimodality therapy consists of an initial biopsy, aggressive combination of surgery, chemotherapy and localized radiotherapy which are the therapeutic choices for Ewing sarcoma of the head and neck region and may result in a long-term survival. The prognosis of Ewing sarcoma is poor because hematogenous spread and lung metastases occur within a few months after diagnosis. The tumor burden is considered today as an important factor of prognosis (16). The conventional imaging like CT and MRI are highly recommended for an accurate evaluation of lesion's prognosis on soft tissue and bone before initiation of treatment. ^{18}F -FDG PET/CT was also used in this case to determine the extent and aggression of the tumor.

In summary, a case of Ewing sarcoma in a young child highlighting diagnostic radiological feature in the mandible was reported. Familiarity with radiological findings will enable the clinician to rule out more common inflammatory lesions and narrow down differential diagnosis.

References

1. Esiashvili N, Goodman M, Marcus RB Jr. Changes in incidence and survival of Ewing sarcoma patients over the past 3 decades: Surveillance Epidemiology and End Results data. *J Pediatr Hematol Oncol.* 2008; 30(6):425-30.
2. Gorospe L, Fernández-Gil MA, García-Raya P, Royo A, López-Barea F, García-Miguel P. Ewing's sarcoma of the mandible: radiologic features with emphasis on magnetic resonance appearance. *Oral Surg Oral Med Oral Pathol Oral Radiol Endod.* 2001; 91(6):728-34.
3. Gosau M, Baumhoer D, Ihrler S, Kleinheinz J, Driemel O. Ewing sarcoma of the mandible mimicking an odontogenic abscess - a case report. *Head Face Med.* 2008; 4:24.
4. Brazão-Silva MT, Fernandes AV, Faria PR, Cardoso SV, Loyola AM. Ewing's sarcoma of the mandible in a young child. *Braz Dent J.* 2010; 21(1):74-9.

5. Keshani F, Jahanshahi G, Attar BM, Kalantari M, Razavi SM, Hashemzade Z, et al. Ewing's sarcoma in mandibular similar to dental abscess. *Adv Biomed Res.* 2014; 3:62.
6. Balkaya E, Bozkurt C, Aksu AE, Özmen S, Özdemir Sİ, Şahin G. Ewing's sarcoma of the mandible misdiagnosed as periodontal inflammation: Report of three cases. *Turk J Pediatr.* 2017; 59(6):704-7.
7. Behnia H, Motamedi MH, Bruksch KE. Radiolucent lesion of the mandibular angle and ramus. *J Oral Maxillofac Surg.* 1998; 56(9):1086-90.
8. Treglia G, Salsano M, Stefanelli A, Mattoli MV, Giordano A, Bonomo L. Diagnostic accuracy of ¹⁸F-FDG-PET and PET/CT in patients with Ewing sarcoma family tumours: a systematic review and a meta-analysis. *Skeletal Radiol.* 2012; 41(3):249-56.
9. Sharma P, Khangembam BC, Suman KC, Singh H, Rastogi S, Khan SA, et al. Diagnostic accuracy of ¹⁸F-FDG PET/CT for detecting recurrence in patients with primary skeletal Ewing sarcoma. *Eur J Nucl Med Mol Imaging.* 2013; 40(7):1036-43.
10. Margaix-Muñoz M, Bagán J, Poveda-Roda R. Ewing sarcoma of the oral cavity. A review. *J Clin Exp Dent.* 2017; 9(2):e294-e301.
11. Vohra VG. Roentgen manifestations in Ewing's sarcoma. A study of 156 cases. *Cancer.* 1967; 20(5):727-33.
12. Lopes SL, Almeida SM, Costa AL, Zanardi VA, Cendes F. Imaging findings of Ewing's sarcoma in the mandible. *J Oral Sci.* 2007; 49(2):167-71.
13. Gupta K, Pawaskar A, Basu S, Rajan MG, Asopa RV, Arora B, et al. Potential role of FDG PET imaging in predicting metastatic potential and assessment of therapeutic response to neoadjuvant chemotherapy in Ewing sarcoma family of tumors. *Clin Nucl Med.* 2011; 36(11):973-7.
14. Harrison DJ, Parisi MT, Shulkin BL. The role of ¹⁸F-FDG PET/CT in pediatric sarcoma. *Semin Nucl Med.* 2017; 47(3):229-41.
15. Quartuccio N, Fox J, Kuk D, Wexler LH, Baldari S, Cistaro A, et al. Pediatric bone sarcoma: diagnostic performance of ¹⁸F-FDG PET/CT versus conventional imaging for initial staging and follow-up. *AJR.* 2015; 204(1):153-60.
16. Yogesh TL1, Shetty A2, Keswani H1, Rishi D. Aggressive high-grade Ewing's sarcoma of maxilla: A rare case report. *J Oral Maxillofac Pathol.* 2018; 22:S48-S53.